

## CLINICAL CASES: DELAYED PREGNANCIES

**Kevin D. Dippert, PhD, PAS**  
**Director, Equine Reproduction Concepts, LLC**

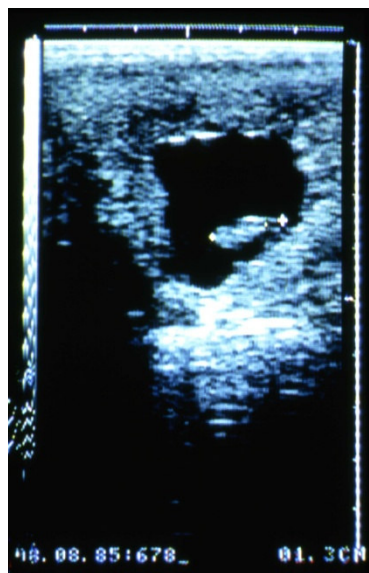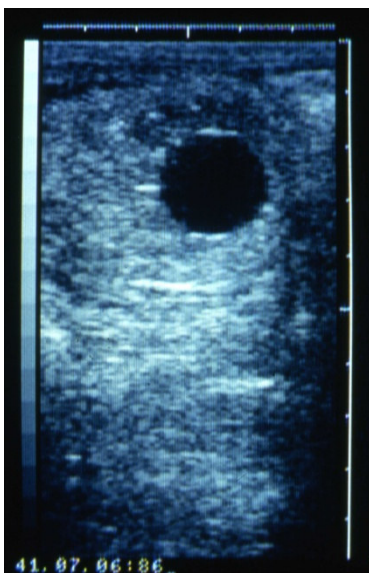
*(Original Print-1999)*

An 11-year-old, Quarter Horse mare was sent to ERC in the early spring for foaling purposes. The foaling went very well with no complications. After a culture and cytology was performed, the mare was rebred. Fourteen (14) days after ovulation a pregnancy exam found that she was not pregnant. A preovulatory-sized follicle (35 mm) was present on her right ovary and it appeared that uterine edema was beginning to develop. This would be indicative of a mare coming into heat. Two days later, she had a 45-mm follicle with prominent edema (Grade 2) to the uterus so we elected to breed her. Ovulation was detected two days after breeding with uterine edema greatly diminished. As the uterus was being scanned to assess fluid retention and uterine edema we stumbled upon a perplexing finding. Alongside a small pocket of residual fluid from the breeding, a spherical structure approximately 12 mm in diameter was noticed. This structure could only be one of two possibilities, a uterine cyst or an embryo. Careful examination identified specular reflections on the upper and lower curvature thus indicating an embryo. However, the size of this vesicle was much smaller than would be for a now 18-day pregnancy. Twelve millimeters is more like a 12- to 13-day pregnancy. Because of the size discrepancy, it was speculated that the vesicle was probably a uterine cyst that had developed during the heat

period. Still curious, we mapped out where it was in the uterus and examined the mare a day later. Much to our amazement, the vesicle had moved from the left horn to the right body of the uterus, now measuring 13 mm in diameter. Since cysts do not move around it was quite obvious that we had a pregnancy on our hands. Now we have a mare that had developed a preovulatory follicle in which she was bred on and subsequently ovulated while she still had a pregnancy from the previous cycle.

This was the first time we've ever seen these circumstances. Even though we were pleased to find a pregnancy, no one was optimistic that it was going to survive. It was obviously growing at a retarded pace along with being exposed to fluid in the uterus from breeding. Our only option as we saw it was to immediately put the mare on Regumate and hope that the uterus would continue to absorb the fluid while allowing the embryo to grow. An examination two days later found no evidence of any fluid or embryo. A rather fitting conclusion to the story occurred. She was indeed pregnant following the second breeding cycle. A healthy 14-day vesicle measured 17 mm in diameter.

Pregnancies with retarded growth clearly indicate that something is wrong with the developing embryos. The assumption is that either an infection, genetic defect, low



**Figure 1 (Upper Left).** A 14-day embryonic vesicle measuring 17 mm in diameter. **Figure 2 (Upper Right).** A 24-day pregnancy with a 13 mm fetus and 32 mm vesicle.

progesterone levels or insufficient interaction between embryo and uterus is responsible for this type of early embryonic loss. This year we found 4 cases in which either a 12- or 14-day pregnancy exam failed to identify a vesicle only to have one appear 2 to 7 days later, much smaller in size than normal. Two cases were mares bred to keep the pregnancies and two cases were recipients that had received cooled embryos. It is not uncommon for cooled embryos to be delayed a little in growth since the cooling process is supposed to slow metabolism.

However, the growth rate should resume a normal pattern once the embryo is firmly established in the uterus. Three of the 4 pregnancies lost the vesicles shortly after identification. One pregnancy from a transfer of a cooled embryo continued growing at a normal rate up through a pregnancy exam at 50 days. Infection can probably be ruled out as a cause since 2 of the 3 open mares became pregnant again without any treatment and the third mare was cultured and found to have no bacterial growth in the uterus.