

CLINICAL CASES: BIG BABIES!

Kevin D. Dippert, PhD, PAS
Director, Equine Reproduction Concepts, LLC
(Original Print-1998)

Two rather unexpected findings occurred during a couple of embryo recovery attempts. As mentioned earlier, an embryo approximately 10 days of age (3,152 microns, or 3.1 mm) was visibly seen rolling through the catheter system and into the filter cup during an anticipated recovery of a Day-7 embryo. Four days later, a 9.5 day (2,668 microns) embryo was also recovered unexpectedly. What we did not elaborate on earlier was the difficulty in trying to work with these embryos and the low success rate in obtaining pregnancies. It is undesirable to transfer embryos greater than 8.5 days of age because they eventually get too big to handle easily. As the embryo increases in size, it becomes more fragile to work with thus increasing the chance of damage during the transfer procedure. At our facility, handling embryos is usually done with a sterile, ¼-ml straw. In working with the first embryo, we had quickly discovered that it was too big to fit into a straw of this size so an alternative had to be found. The next approach was to try a straw (½ ml) normally used for freezing semen but that also failed to be useful. Our last approach was to bypass a straw method and directly draw the embryo up into a sterile insemination pipette. These pipettes are 22" long and have an inner diameter that is barely 3 mm in size. Although the equipment was certainly different than what's typically used, the principle for transfer was the same. By carefully entering the vagina with the pipette in-hand, the cervix was located and manipulated so a clear path to the uterus was created. Once there was a passageway, the pipette was guided into the uterus and the embryo deposited. A comment jokingly made at the time was to scan the mare immediately after the

transfer to see the embryo and declare her successfully pregnant. In all actuality, embryos can be detected via ultrasound at 10.5 to 11 days of age, being 3 to 4 mm in size. We wanted to wait 2 days however and see if the mare had recognized the embryo as a pregnancy. Our hopes were appropriately guarded because previous work by many researchers clearly found lower pregnancy rates with embryos 9 days of age or older. One study by Iuliano

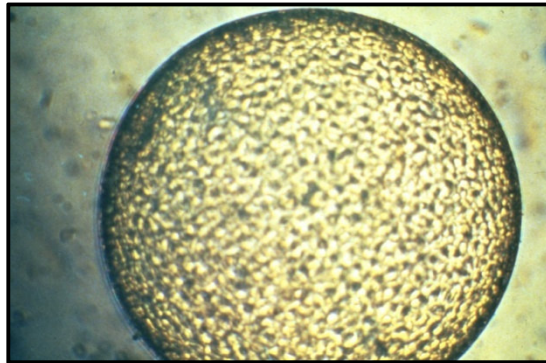
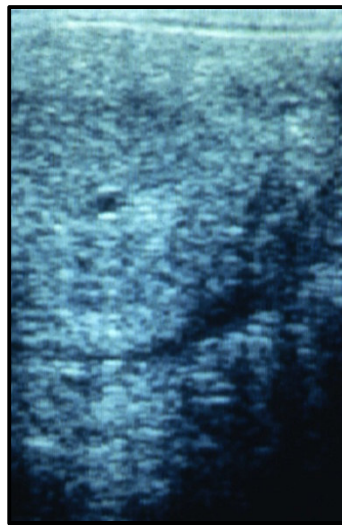


Figure 1 (Upper). Embryo at the expanded blastocyst stage of development. This developmental stage is seen with all embryos greater than 7.5 days of age.

Figure 2 (Lower). Ultrasonographic image of a Day-10.5 embryo within the uterus.



noted a 12% pregnancy rate at day 50 when a mean embryo size of 1.76 mm (~8.5 days of age) was nonsurgically transferred. Much to our amazement, an ultrasound exam confirmed that the mare was indeed pregnant 2 days after transfer with a healthy looking 9 mm vesicle. At day 50 of gestation, the recipient mare was still pregnant and subsequently sent to a new home. We were less fortunate however with the second large embryo recovered. Efforts failed to obtain a pregnancy following similar procedures.